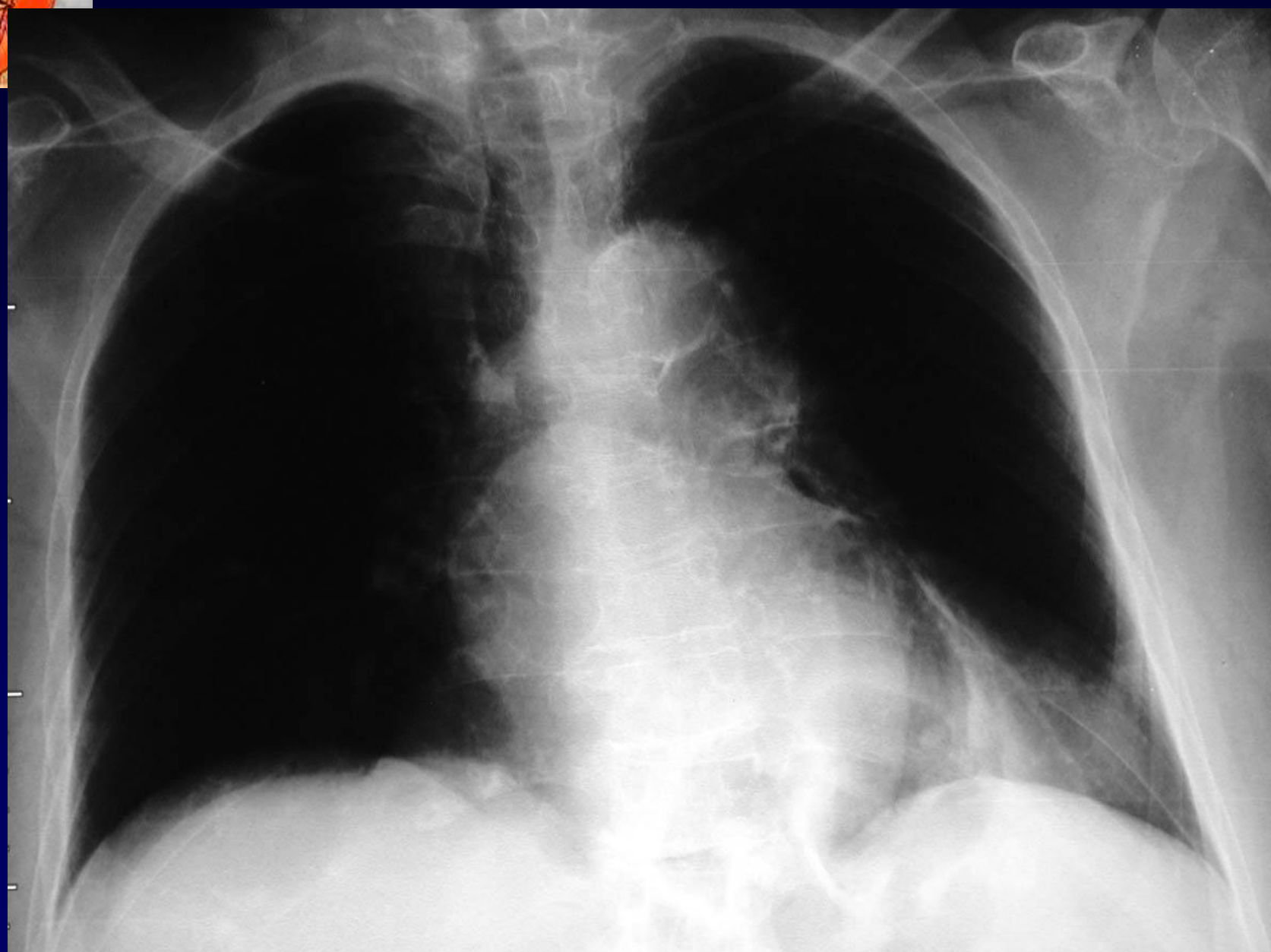
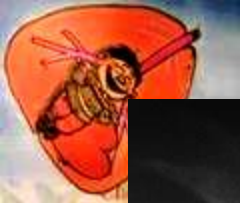



LMETGE

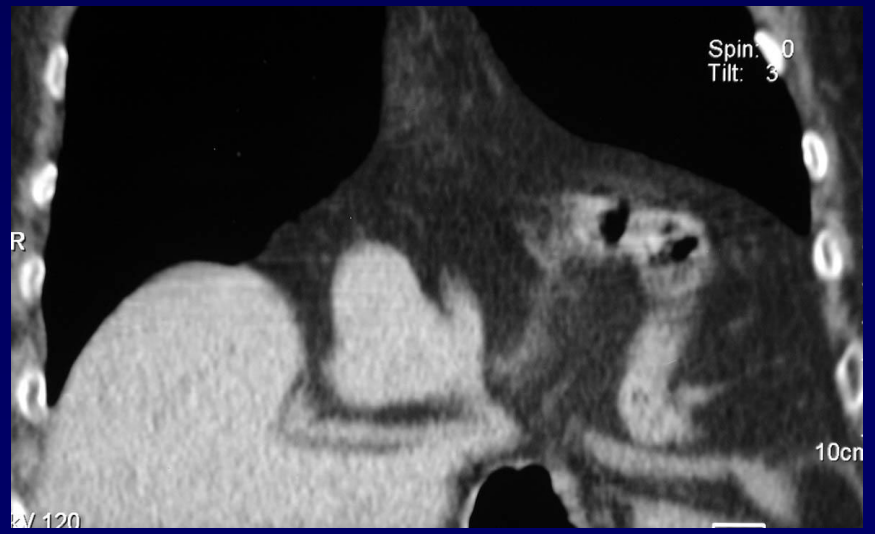
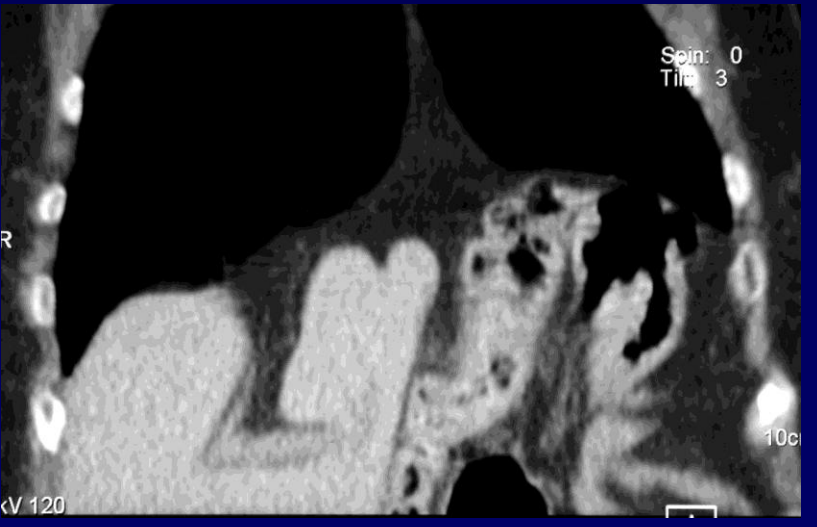
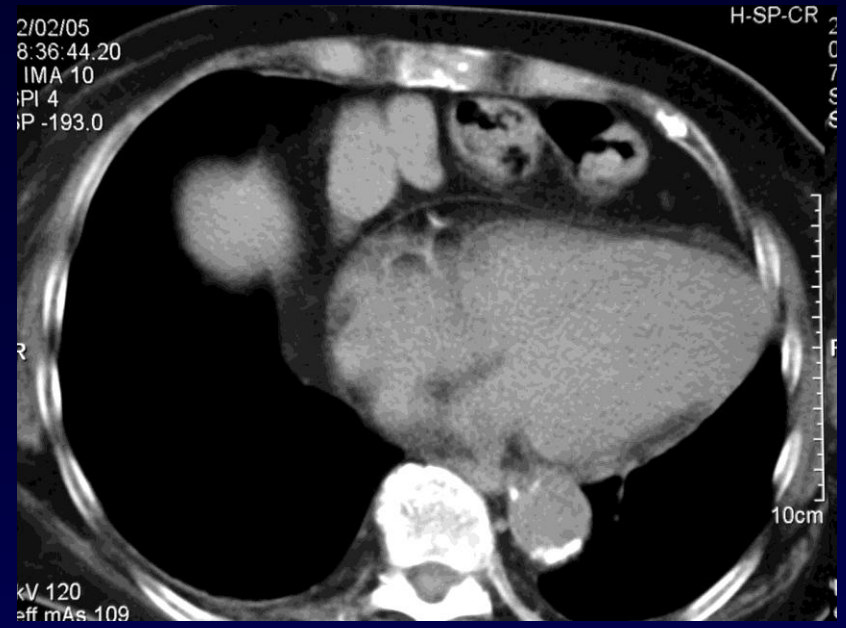
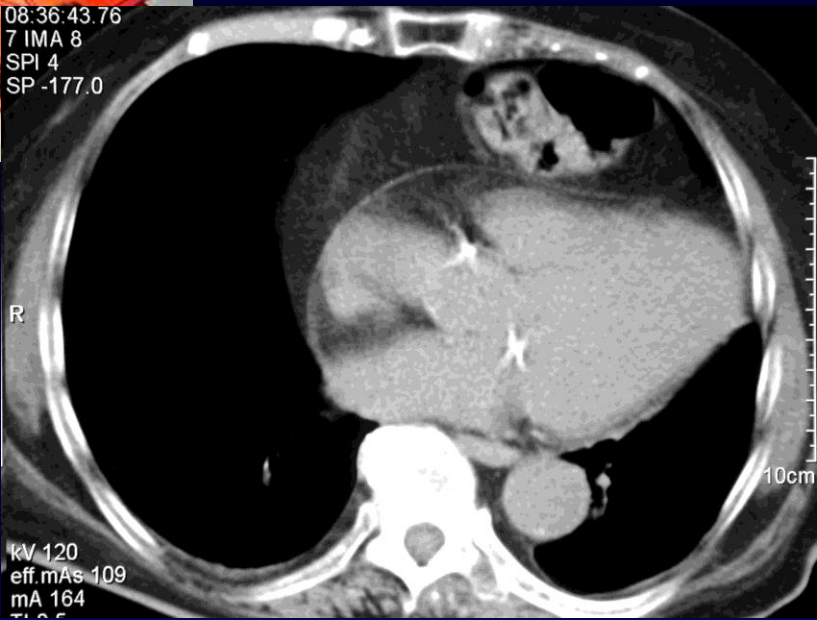
Femme de 85 ans

Radiographie thoracique effectuée dans le cadre du bilan lors d'une tentative de suicide par médicaments





08:36:43.76
7 IMA 8
SPI 4
SP -177.0





Diagnostic ?



Hernie par la fente de Larrey